ISSN: 2519-7053 (Print)
ISSN: 2519-7878 (Online)

NJHS

National Journal of Health Sciences

Vol. 10, No. 4,

2025

Quarterly

- *Breakthrough Pharmacotherapy Redefining Obesity Management*
- *E-Cigarette Use Linked to Significant Oral Health Complications*
- *Critical Gaps in VTE Prophylaxis for Pregnant Women*

NiBD Publications

www.njhsciences.com

NJHS
National Journal of Health Sciences

Editorial Board

Editorial Team

Patron-in-Chief
Mr. Mohiuddin Chawla

Editor-in-Chief
Dr. Tabinda Ashfaq
MBBS, FCPS, FRCGP
Outreach Clinical Lead, Department of Family Medicine, The Aga Khan University, Karachi, Pakistan.

Editor
Dr. Tasneem Farzana
MBBS, MCPS, Dip Haem, FRCP (London)
National Institute of Blood Disease & Bone Marrow Transplantation, Lahore Campus, Pakistan.

Managing Editor
Muhammad Akif Ali Atif

Founding Editor-In-Chief
Dr. Tahir S. Shamsi (Late)
MBBS, MRCPath, FRCPath
National Institute of Blood Disease & Bone Marrow Transplantation, Karachi, Pakistan.

Advisory Board

Dr. Fatima Riaz
MBBS, FCPS (Family Medicine), MRCGP (International) Family Medicine
Department of Family & Community Medicine, College of Medicine, King Khalid University Abha, KSA

Dr. S.H. Waqar
MBBS, FCPS, MCPS-HPE, FACS, CME
PIMS and Federal Medical College, Islamabad, Pakistan.

Dr. Tabinda Ashfaq
MBBS, FCPS, FRCGP
Outreach Clinical Lead, Department of Family Medicine, The Aga Khan University, Karachi, Pakistan.

Dr. Tasneem Farzana
MBBS, MCPS, Dip Haem, FRCP (London)
National Institute of Blood Disease & Bone Marrow Transplantation, Lahore Campus, Pakistan.

National

Dr. Abdul Majeed Chaudhry
MBBS, FRCS, FCPS, MHPE, FCSSL, FASI
Lahore Medical & Dental College, Lahore, Pakistan.

Dr. Aizaz Mand Ahmad
MBBS, FCPS (Medicines), FCPS (Nephrology), FRCP (London)
Evercare Hospital Lahore, Pakistan.

Dr. Farid Ahmed
MBBS, FCPS, FRCS (UK)
Alrazi Health care, Surgimed Hospital, Lahore, Pakistan.

Dr. Nazish Saqlain
MBBS, FCPS (Haematology)
Postgraduate Medical Institute/ Ameer-ud-din Medical College/ Lahore General Hospital, Lahore, Pakistan.

Dr. Nazli Hossain
MBBS, FCPS (Obs & Gyne), MBE
Dow University of Health Sciences, Karachi, Pakistan.

Dr. Qamaruddin Baloch
MBBS, FCPS (Surgery)
Al-Tibn Medical College & Hospital Isra University Karachi Campus, Pakistan.

Dr. Rahat-Ul-Ain
MBBS, FCPS (Paeds), FCPS (Paeds/ Haem/Onco)
The Children's Hospital and Institute of Child Health, Lahore, Pakistan.

Dr. S.H. Waqar
MBBS, FCPS, MCPS-HPE, FACS, CME
PIMS and Federal Medical College, Islamabad, Pakistan.

Dr. Soufia Farrukh
F.C.P.S, F.R.C.S. (Glasgow)
Ophthalmology PGD & MSc (MED. EDU.)
Quaid-e-Azam Medical College, Bahawalpur, Pakistan.

International

Dr. Gulali Aktas
MD, PhD (Internal Medicine)
Department of Internal Medicine in Faculty of Medicine, Abant Izzet Baysal University, Golkoy, 14030, Bolu, Trkiye.

Dr. Mohiuddin Ahmed Khan
MBBS, FCPS (Hematology, BCPS, FRCP)
Department of Hematology, Dhaka Medical College Hospital, Dhaka, Bangladesh.

Dr. Muhammad Akram
M.D., M.B.A., F.A.C.C., F.S.C.A.I.(Cardiology)
Cardiac Center of Texas, USA.

Dr Najam Us Saqib
M.B., B.S., DA (Eng.), FCARCS (Ire.)
Doncaster & Bassetlaw NHS Foundation, Bassetlaw Hospital, United Kingdom.

Dr. Suleman Atique
PhD (Biomed. Informatics)
Department of Obstetrics and Gynecology, Oslo University Hospital (OUH), Rikshospitalet, Oslo, Norway.

Editorial Secretariat

Ms. Maria Baig
Editorial Manager

Published under No. DC/EAST/HVC/Leg Br.24/2016 for NIBD Publications and printed at KAGZI Printers, Karachi, Pakistan.

Plot # 16, Maqbool Society, Block 7-8, Lal Muhammad Chaudhry Road, Karachi 75350, Pakistan.
(92 21) 34392398 & 34392399, www.njhsciences.com

Note: ORCID® is a registered trademark and the ORCID logo and iD icon are trademarks of ORCID, Inc.

NJHS
National Journal of Health Sciences

About Us:

The National Journal of Health Sciences (NJHS) is the official publication of the National Institute of Blood Disease & Bone Marrow Transplantation (NIBD & BMT), Karachi, Pakistan. The journal serves as a dedicated platform for healthcare professionals, fostering the dissemination of substantial and credible contributions to the field of health sciences.

National Journal of Health Sciences publishes high-quality, peer-reviewed scholarly articles encompassing a wide range of research disciplines in both electronic and print formats. The journal offers an efficient and user-friendly submission system designed to facilitate a smooth and timely publication process. All submitted manuscripts undergo a rigorous double-blind peer review process, ensuring the highest standards of academic integrity and scientific excellence.

Each issue of National Journal of Health Sciences features clinically relevant and evidence-based research, readily accessible to the medical professionals, with the aim of advancing healthcare knowledge and fostering research development across the health sciences community.

Vision Statement:

The National Journal of Health Sciences is committed to driving trans-formative progress in healthcare by fostering interdisciplinary collaboration, advancing equity in scientific dialogue, and promoting excellence in research dissemination.

We envision a future where high-quality, evidence-based knowledge serves as the foundation for measurable improvements in patient outcomes, healthcare systems, and population health worldwide.

Mission Statement:

At National Journal of Health Sciences, our mission is to uphold the highest standards of ethical integrity and scholarly excellence in health sciences publishing. We provide an inclusive and dynamic platform for the dissemination of rigorously reviewed research, aligned with international best practices, including ICMJE, COPE, and EQUATOR guidelines.

Committed to fostering transparent scientific dialogue, we emphasize robust peer review, editorial integrity, and equitable access to knowledge. By championing innovation, diverse perspectives, and translational relevance, National Journal of Health Sciences empowers researchers and healthcare professionals to address critical health challenges and contribute to sustainable, evidence-based solutions that advance global healthcare.

Disclaimer:

The content published in the National Journal of Health Sciences (NJHS), including but not limited to research articles, reviews, editorials, perspectives, letters to the editor, case reports, short communication reflects the views and opinions of the individual authors and does not necessarily represent the official position or endorsement of National Journal of Health Sciences, its Publisher, Editorial Board, Editors, or Editorial Staff. Authors are solely responsible for the accuracy, integrity, and originality of their submitted and published work, including all data, analyses, interpretations, and conclusions. This responsibility extends to ensuring compliance with ethical guidelines, research standards, and applicable laws, including those related to copyright, intellectual property, and data privacy.

National Journal of Health Sciences, its Publisher, Editorial Board, Editors, and Editorial Staff disclaim any liability for:

Errors or omissions: We do not warrant the completeness or accuracy of the information published. **Consequences of use:** We shall not be held liable for any direct, indirect, incidental, consequential, or punitive damages arising from the use of or reliance on the content published in National Journal of Health Sciences. **Third-party content:** We are not responsible for the content of any external websites or resources linked to or referenced in the journal. **Ethical breaches:** Authors are responsible for ethical compliance, and National Journal of Health Sciences (NJHS) shall not be held liable for any ethical breaches committed by authors. **Legal liabilities:** We are not responsible for any legal issues that may arise from the publication of authors' content.

Authors warrant that their submissions are original, do not infringe upon the rights of others, and have not been previously published or are under consideration for publication elsewhere, except as disclosed in their submission. Authors agree to indemnify and hold harmless National Journal of Health Sciences, its Editorial Board, Editors, and Editorial Staff from any claims, liabilities, or expenses arising from their published work.

By submitting a manuscript to National Journal of Health Sciences, authors acknowledge that they have read, understood, and agreed to this disclaimer and its terms. This disclaimer is subject to change without notice.

NJHS
National Journal of Health Sciences

Table of Content
Volume 10, Issue 4, 2025

Editorial

220 Transforming Obesity Care: Medications at the Forefront

Tabinda Ashfaq

Research Articles

222 Association of E-Cigarette Use and Oral Health Complications: A Cross Sectional Study in Punjab, Pakistan

Muhammad Taaha, Naila Umer, Hafiz Danish Altaf, Rabia Anjum, Hammad Hassan, Safi Ullah Khan

230 Is Obesity Associated with a Higher Risk of Differentiated Thyroid Cancer in a Cytologically Proven Series of Thyroid Nodules?

Irfan Ahmed Shaikh, Danish Ur Rehman, Sidra Bano, Rajesh Kumar, Ramsha Khalid, Raheem Bakhsh

238 Diagnostic Accuracy of Ultrasound in Detecting Axillary Lymph Nodes in Patients with Early Breast Cancer Taking Histopathology as a Gold Standard

Ambreen Shaikh, Saleha Anwar, Hasnain Ali, Raisa Altaf Malik, Humaira Erum, Bisma Rizwan

244 Role of Heparin to Prevent Hypertrophic Scarring in Donor Area of Split Thickness Skin Graft

Asma Ishtiaq, Faisal Akhlaq Ali Khan, Farhan Zahid, Iqra Muhammad Tasleem, Asra Zahid, Nasreen Bano Khatri

251 Outcomes of Intestinal Anastomosis with or without Platelet Rich Plasma Application

Syeda Wajiha Mustafa, Malik Asad Munir, Atika Tahir, Batool Fatima, Muhammad Azam Mirza, Muhammad Kashif Bashir

258 Risk Assessment of Venous Thromboembolism in Pregnancy and Adequate Prophylaxis: An Observational Study

Aliya Nasim, Sagheera Anjum Manaver, Naima Shah, Humaira Tahir, Mehvish Kanval

264 Experience in Pediatric Bleeding Disorders in Tertiary Care Health Services from Southern Region of Saudi Arabia: Single Center Retrospective Study

Badriah Gharamah Al Asmari, Ali Mujtaba Tahir, Mohammed Alpakra, Mohaned Mustafa Ahmed Mohammad, Sara Saeed Mahamoud Hassanien, Mahnoor Saeed, Manea Abdullah Alqarni, Sami Saleh Alamri

271 Prevalence of Depression and Anxiety in Patients with Obstructive Lung Disease and Correlation with Spirometry

Ehab Nabeel, Sohail Akhtar, Ahmed Ali, Syed Wajahat Hussain, Mujahid Hussain

279 In-Hospital Outcomes of Early Extubation in Post CABG Patients: A Retrospective Study from a Tertiary Care Hospital in Karachi, Pakistan

Qaiser Aziz Khan, Latifa Haidari, Imran Khan Sandeelo, Marium Nastaeen Sarhandi, Sarib Bin Yasir, Mariam Amir

287 Knowledge, Attitudes & Perceptions towards Premenstrual Syndrome among Low Socioeconomic School-Going Adolescent Girls in Karachi, Pakistan

Shaikh Ali Masood, Shabbir Ahmed Mallick, Hamna Jamal, Maria Murtaza, Manahil Nadeem, Ameera Shabbir

292 Timing of Surgical Intervention and its Impact on Short-term Outcomes in Pediatric Hydrocephalus

Shakeel Ahmed, Shoaib Saleem Khan, Syed Zahid Hussain Shah, Muhammad Ali Waqas, Ubaid Ullah, Zeeshan Karim

Case Report

299 Spontaneous Resorption of Mandible in a Middle Aged Female

Hafiz Muhammad Bilal Siddiqui, Hafiz Murtaza Hussain, Talha Ahmed Qureshi, Mariam Mubashir

Research Article

Diagnostic Accuracy of Ultrasound in Detecting Axillary Lymph Nodes in Patients with Early Breast Cancer Taking Histopathology as a Gold Standard

Ambreen Shaikh*, Saleha Anwar, Hasnain Ali, Raisa Altaf Malik, Humaira Erum, Bisma Rizwan

Department of Diagnostic Radiology, Liaquat National Hospital Karachi, Pakistan.

Abstract: Background: Axillary Ultrasound plays an essential role in assessment of axillary lymph nodes metastasis in early breast cancer. It is considered as important prognostic factor in the recurrence of the disease and survival of the patient.

Objective: The study was aimed to determine ultrasonography's diagnostic accuracy taking histopathology as a Gold Standard in finding axillary lymph nodes in early CA breast patients.

Materials and Methods: Study was designed as cross-sectional, conducted at Department of radiology, Liaquat National Postgraduate Medical Center, Karachi. The sample size calculated for the study was 271. Patients of age between 18-65 years were included in the study. Sensitivity, specificity, PPV, NPV and diagnostic accuracy were calculated.

Result: The mean age of the participants was 46.28 ± 9.76 years. The age range from 25 years to 78 years. The study has yield a sensitivity of 76.9% whereas specificity was reported 68.2%. The overall diagnostic accuracy of AUS was observed as 74%. A positive predictive value and negative predictive value was 88.8% and 52.7% respectively.

Conclusion: The findings of this study provides information related to the diagnostic accuracy of AUS as a detection tool for early breast cancer. The findings of this study are consistent with the existing literature showing high sensitivity and accuracy of the tool pointing out that AUS can serve as a reliable means of identification of patients who have axillary metastasis.

Keywords: Axillary ultrasound, Histopathology of breast cancer, Diagnostic tools, Axillary lymph nodes, Metastasis, Human Papilloma Virus.

INTRODUCTION

Breast cancer is utmost frequent cancer among females globally [1, 2]. Breast cancer accounts for 15% of all new diagnosed cases of cancer in the advance countries likes UK [3]. Furthermore, breast cancer is the second leading cause of death among women and the fourth leading cause of cancer death in the UK reported in years 2018, accounting for about 7% of all deaths due to cancer. In UK, approximately 98% of people, diagnosed with CA breast at the earliest stage live for at least for more five years, however the five-year survival rate reduces to round about 26% for those detected at a later stage [4]. The prognostic estimate and all in all, the survival of breast cancer patients is majorly influenced by the existence of metastases in axillary lymph node (LN) [5].

Axillary lymph node dissection (ALND) for axillary staging in CA breast was once the standard but involves a higher risk of adverse effects. Sentinel lymph node biopsy (SLNB) is now considered as the gold standard for early-staging of CA breast [6]. It is associated with a fewer adverse events after the procedure [7]. SLNB not only prevents unnecessary ALND but also supports in determining the number of lymph nodes that are involved in it. It is very crucial for selecting adjuvant therapy in CA breast. On the other hand, 1–15% of all the patients with negative SLNB even have diseased lymph nodes in the same site, mainly due to extensive metastases in nodes as the first node to drain [7].

Axillary ultrasound (AUS) is commonly used in baseline evaluations in early CA breast. It is recommended by the current guidelines. It plays an essential role in assessment of axillary lymph nodes condition [8]. It is considered as important prognostic factor in the recurrence of the disease and survival of the patient. Emerging strategies, such as targeted axillary dissection (TAD) and axillary marking, are intended to identify patients that do not require ALND requiring pre-therapeutic AUS identification and post-neoadjuvant re-evaluation [9]. The evaluation of the benefits and effectiveness of ALND is the ACOSOG Z0011 trial, done to demonstrate that ALND could be omitted in case of limited SLN metastasis without affecting the survival of women undergoing the BCS. AUS has been shown to have different sensitivities and specificities in identifying the presence of lymph node involvement [10]. For instance, Riedle *et al.* reported sensitivity 53.3% and specificity 93.7% [11]. According to the study of Reshkallah *et al.* the sensitivity, specificity and diagnostic accuracy were found to be 59.6%, 95.1% and 82.2% respectively [12].

* Address correspondence to this author at the Department of Diagnostic Radiology, Liaquat National Hospital Karachi, Pakistan.
Email: ambreenshaikh796@gmail.com

 © 2025 NIBD Publications

Although the histopathological assessment is the gold standard to establish diagnosis of lymph node involvement, however, due to the invasive nature of histopathological examination and the potential complications that may be associated with it, ultrasound has become a non-invasive and cost-effective alternative to assess lymph node involvement [13]. By matching the ultrasound findings to finding results from histopathology, the research study aimed to find the accuracy of ultrasound which can reduce the need for invasive procedures and enhance breast cancer management protocols. The study has the potential to significantly impact patient care by providing a more efficient diagnostic pathway and improving treatment planning. Therefore, the study was aimed to determine ultrasonography's diagnostic accuracy taking histopathology as a Gold Standard in finding axillary lymph nodes in early CA breast patients.

MATERIALS AND METHODS

The study was designed as cross-sectional investigation. It was conducted after approval from Ethical Review Committee (ERC) (Ref: App#1129-2024-LNH-ERC) of the Liaquat National Hospital, Karachi. It was conducted at Department of Radiology, Liaquat National Postgraduate Medical Center, Karachi, Pakistan. The study duration was from March, 2025 to May 2025. Prevalence of lymph nodes in early breast cancer was 34.7% [11], margin of error 10% (sensitivity and specificity 59% and 88.4% respectively [14]), and confidence level 95%. The sample size calculated for the study was 269. Sampling technique used was non-probability consecutive. Patients of age between 18-65 years were included in the study. Patients those were diagnosed with early breast cancer were considered part of study. Patients excluded from the study were known metastatic disease, recurrent breast cancer and patients on chemotherapy or radiotherapy. All patient diagnosed with early breast cancer referred to radiology department for axillary ultrasound and met the inclusion criteria were enrolled. Prior to enrolment complete details of the study were explained to the patients and written informed consent was taken before using the diagnostic tools.

After taking consent baseline demographic and clinical details such as age, residence and laterality were taken. All patient with early breast cancer were undergone axillary ultrasound performed by expert sonologist, who was having more than 5 years of experience in the field of sonography, and findings regarding the lymph node were noted. A high-frequency (7–15 MHz) linear-array transducer was used to examine both breasts using ultrasound. All quadrants, the retroareolar area, and the axillary tail were methodically scanned in the radial and antiradial planes. When appropriate, color Doppler assessment was added to real-time grayscale imaging to determine lesion features and vascularity. After ultrasound all patient were undergone histopathology for confirmation of diagnosis. Later findings of ultrasound and histopathology were compared to calculate the diagnostic accuracy.

STATISTICAL ANALYSIS

Data was analyzed using SPSS version 25. Frequency and percentage were reported for qualitative variables such as laterality, stage of cancer, lymph node on ultrasound and lymph node on histopathology. While mean (SD) or median (IQR) were calculated for quantitative variables such as age on the basis of normality using Shapiro Wilk test. Sensitivity, specificity, PPV, NPV and overall diagnostic accuracy were computed with their 95% confidence interval for assessing diagnostic accuracy.

RESULT

A total of 271 patients were studied. Study finds shows the mean age of the participants was 46.28 ± 9.76 years. The age range from 25 years to 78 years. The family history of breast cancer was reported in 99 (36.5%) of the patients as shown in Table **1**.

Table 1. Characteristics of Participants and Clinical Findings.

Characteristics		N (%)
Age	46.06 +/- 9.08*	
Laterality	Left	131 (48.3%)
	Right	140 (51.6%)
Family History	Yes	99 (36.5%)
	No	172 (63.4%)

*Age: Mean ± SD.

Patients diagnosed with axillary U/S were 180 (66.4%), while on histopathology diagnosis of the early metastases into the axillary lymph nodes were made in 208 (76.7%) of the cases as shown in Table **2**. Fig. (**1**) displays details of histopathological findings. Fig. (**2**) depicts ultra sound findings. Fig. (**3**) shows evidence of malignancy on histopathology.

Table 2. Diagnosis of Early Breast Cancer with U/S and Histopathology.

	Findings	Ultrasound	Histopathology
Early Breast Cancer	Positive, n(%)	180 (66.4%)	208 (76.7%)
	Negative,n(%)	91 (33.5%)	63 (23.2%)

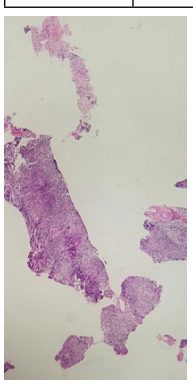

Fig. (1). This Photomicrograph Depicts Lymphoid Cells Showing a Neoplastic Lesion Arranged in Cohesive Clusters and Nests. Tumor Cells show Altered Nuclear-to-Cytoplasmic (N:C) ratio, Nucleomegaly and Hyperchromasia, Manifesting Malignant Transformation.

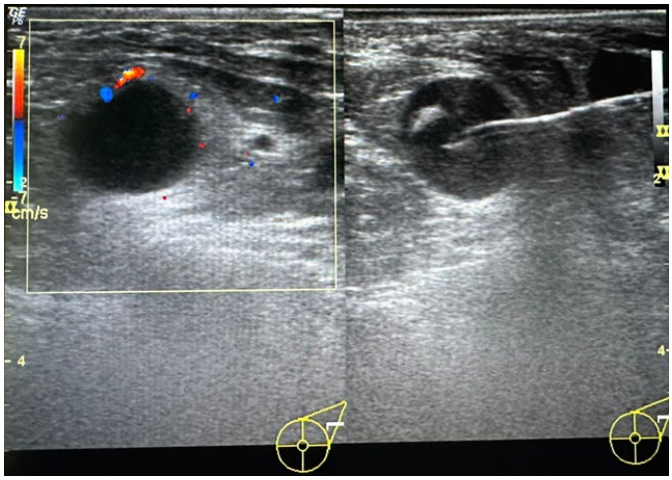

Fig. (2). This is Ultrasound Image of Left Axilla Showing a Rounded Hypoechoic Axillary Lymph Nodes with Loss of Fatty Hila. Color Doppler Imaging (CDI) Exhibits Peripheral Vascularity, Suggestive of a Metastatic Lymph Node.

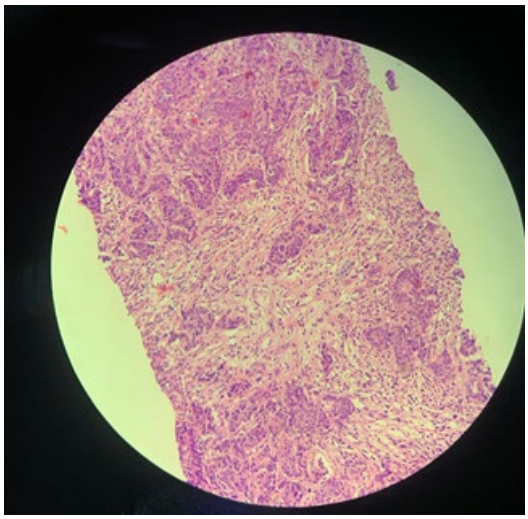

Fig. (3). Linear Fragments of Small to Medium Size Lymphocytes with no Evidence of Malignancy.

The comparison of axillary U/S and histopathology showed 160 true positive cases and false negatives were 48 as show in Table **3**. The sensitivity of the diagnostic tool was found to be 76.9% and specificity as 68.2%. Positive predictive value PPV was as 88.8% in diagnosed cases with a p-value of <0.001 as shown in Table **4**.

Table 3. Screening Results of U/S and Histopathology Test.

U/S	Histopathology		
	Positive	**Negative**	**Total**
Positive, n	TP (160)	FP (20)	180
Negative, n	FN (48)	TN (43)	91

TP: True positive, FP: False positive, FN: False negative, TN: True negative.

Table 4. Diagnostic Accuracy of U/S in Detecting Early Breast Cancer Cases.

Sensitivity (%) with 95% CI	76.9 (71-82)
Specificity (%) with 95% CI	68.2 (56-78)
Diagnostic Accuracy (%) with 95% CI	74.9 (69-80)
Positive Predictive Value (%) with 95% CI	88.8 (83-89)
Negative Predictive Value (%) with 95% CI	52.7 (37-59)

DISCUSSION

The Axillary Ultrasound (AUS) is considered as an affordable diagnostic tool in low resource settings [15]. It is frequently available and can be used in diagnosing breast cancer at early stage. The evaluation of breast cancer stage can be predicted on the basis of Lymph Node (LN) status. The variations in morphology of cortex in LN provides information about the metastasis [16]. Several studies conduct have discussed the suspected breast lesions and the presence of cancer by using the ultrasound. It especially supports in the diagnosis of metastasis in Axillary Lymph Node (ALN) [17-19]. The study has assessed the diagnostic performance of AUS in detecting axillary lymph node metastasis in breast cancer patients. The study has yield a sensitivity of 76.9% whereas specificity was reported 68.2%. The overall diagnostic accuracy of AUS was observed as 74% and a positive predictive value (PPV) of 88.8% and a negative predictive value (NPV) of 52.7%.

Ultrasound is a radiation-free and non-invasive imaging technique that can be utilized for breast cancer detection [20]. Some previously conducted studies showed similar results which are consistent with the results of our study. A study conducted in Aga Khan University Hospital reported accuracy of AUS as 75%. The sensitivity reported was 61% and specificity of 84.4% [21]. Diagnostic accuracy reported is similar to the reported accuracy of current study. A Study conducted in China, a population based study that involved around 1049 breast cancer cases found that AUS showed sensitivity of 69.9%, while specificity of 81.8%. The overall diagnostic accuracy reported was 77% [22] which was comparable with the results of this study. Another study conducted on UK breast cancer cases showed the diagnostic accuracy of AUS was found to be 71% which is near to the finding of our study. But the reported sensitivity of 54% was found to be lower than the results of our study [23]. In a study conducted on Iranian women showed the diagnostic accuracy of AUS was 76% [24] which is very similar to the results of our study, suggesting consistency in diagnostic accuracy across different healthcare settings.

In resource limited settings, one recent meta-analysis on 76,958 patients revealed that overall pooled sensitivity and specificity was 80.1% and 88.4% respectively, which demonstrates that AUS could be a best primary diagnostic tool for early breast cancer detection [25]. In a breast cancer trails being conducted in over six different settings including China, Nigeria, Argentina and Malaysia showed AUS sensitivity of 89.25 and specificity of 99.1% which is here yield that the findings of our study [26].

The results may vary because in these settings the patients are younger in age and the disease is diagnosed at more advance stage. In a study conducted on patients with Human Papilloma Virus (HPV) metastases of ALN showed Diagnostic sensitivity of 71.7%, specificity of 84.6%, and diagnostic accuracy of 77.6% [27] keeping pathological findings as the Gold standard for diagnosing the ALN metastases.

There is a variability in the existing literature and the finding of the current study. Authors in the literature suggest these variation in the diagnostic accuracy depends on the level of experience of individual examiner performing the procedure. The results are also influenced by the evaluation criteria used during the examination. Studies supported that high sensitivities reported were consistent with the low specificities within the studies and the results were vice versa. The overall global performance of AUS in diagnosing the ALN metastases was not considerably improved.

LIMITATIONS

The study has few limitations that includes progression of the disease cannot be evaluated based on the study design as the current study is a cross-sectional in nature. Another limitation of this study is utilization of AUS in the up-follow of disease progression, which can be eliminated in future researches by using the prospective or follow-up study designs. Further added to the limitation, the study is not generalizable as it was a single center study which hinders the external validation of the data on entire targeted population.

CONCLUSION

The findings of this study provides information related to the diagnostic accuracy of AUS as a detection tool for early breast cancer. The findings of this study are consistent with the existing literature showing high sensitivity and accuracy of the tool pointing out that AUS can serve as a reliable means of identification of patients who have axillary metastasis. Future researches would need to address standardizing AUS protocols, educating monographers to increase diagnostic accuracy and studying adjunctive imaging modalities to enhance axillary lymph node metastasis detection in patients with breast cancer

ABBREVIATIONS

ALND: Axillary lymph node dissection.

AUS: Axillary Ultrasound.

CA: Cancer.

HPV: Human Papilloma Virus.

IQR: Inter-quartile Range.

NPV: Negative Predictive Value.

PPV: Positive Predictive Value.

SLNB: Sentinel Lymph Node Biopsy.

SD: Standard Deviation.

TAD: Targeted Axillary Dissection.

AUTHORS' CONTRIBUTION

Ambreen Shaikh: Conceptualization, Study design, Writing draft, Final approval, final proof to be published.

Saleha Anwar: Study design, Critical review and revision the manuscript, Final approval, final proof to be published.

Hasnain Ali and **Raisa Altaf Malik**: Writing draft, Final approval, final proof to be published.

Humaira Erum and **Bisma Rizwan**: Methodology, Data analysis and interpretation, Final approval, final proof to be published.

ACKNOWLEDGMENTS

Declared none.

ETHICAL DECLARATIONS

Data Availability Statement

Data will be available from the corresponding author upon a reasonable request.

Ethical Approval

ERC approvals were taken before the start of this study (Ref: App#1129-2024-LNH-ERC).

Consent to Participate

All the study participants were enlisted with their written informed consent.

Consent for Publication

All authors give consent for the publication of this work.

Conflict of Interest

None

Competing Interest/Funding

None

Use of AI-Assisted Technologies

The authors declare that no generative artificial intelligence (AI) or AI-assisted technologies were utilized in the writing of this manuscript, in the creation of images/graphics/tables/captions, or in any other aspect of its preparation.

REFERENCES

[1] Syed BM. Rising trend of breast cancer in pakistan-an upcoming major health issue. J Liaquat Uni Med Health Sci 2020; 19(04): 224-5.doi:10.22442/jlumhs.201940694

[2] Khair H. Effectiveness of breast self-examination practices among females in their early twenties. Liaquat Nat J Prim Care 2023; 5(1): 1. DOI: https://doi.org/10.37184/lnjpc.2707-3521.5.15

3] Barclay NL, Burn E, Delmestri A, Duarte-Salles T, Golozar A, Man WY, *et al.* Trends in incidence, prevalence, and survival of breast cancer in the United Kingdom from 2000 to 2021. Scientific Rep 2024; 14(1): 19069. https://doi.org/10.1038/s41598-024-69006-1

[4] Teichgraeber DC, Guirguis MS, Whitman GJ. Breast cancer staging: Updates in the AJCC cancer staging manual, and current challenges for radiologists, from the AJR special series on cancer staging. Am J Roentgenol 2021; 217(2): 278-90. https://doi.org/10.2214/AJR.20.25223

[5] Li P, Sun D. Advanced diagnostic imaging of sentinel lymph node in early stage breast cancer. J Clin Ultrasound 2022; 50(3): 415-21. https://doi.org/10.1002/jcu.23151

[6] Shin E, Yoo TK, Kim J, Chung IY, Ko BS, Kim HJ, *et al.* Evaluating the survival outcomes in clinical node stage 2 and 3 breast cancer patients with negative sentinel lymph node biopsy after neoadjuvant chemotherapy: sentinel lymph node biopsy alone vs. axillary lymph node dissection. Front Oncol 2025; 15: 1563586.

[7] Moorman AM, Rutgers ET, Kouwenhoven EA. Omitting SLNB in breast cancer: Is a nomogram the answer? Ann Surg Oncol 2022; 29(4): 2210-8. https://doi.org/10.1245/s10434-021-11007-9

[8] Man V, Luk WP, Fung LH, Kwong A. The role of pre-operative axillary ultrasound in assessment of axillary tumor burden in breast cancer patients: A systematic review and meta-analysis. Breast Cancer Res Treat 2022; 196(2): 245-54. https://doi.org/10.1007/s10549-022-06699-w

[9] Kontos M, Kanavidis P, Kühn T, Masannat Y, Gulluoglu B. Targeted axillary dissection: Worldwide variations in clinical practice. Breast Cancer Res Treat 2024; 204(2): 389-96. https://doi.org/10.1007/s10549-023-07204-7

[10] Tseng J, Alban RF, Siegel E, Chung A, Giuliano AE, Amersi FF. Changes in utilization of axillary dissection in women with invasive breast cancer and sentinel node metastasis after the ACOSOG Z0011 trial. Breast J 2021; 27(3): 216-21. https://doi.org/10.1111/tbj.14191

[11] Riedel F, Schaefgen B, Sinn HP, Feisst M, Hennigs A, Hug S, *et al.* Diagnostic accuracy of axillary staging by ultrasound in early breast cancer patients. Eur J Radiol 2021; 135: 109468. https://doi.org/10.1016/j.ejrad.2020.109468

[12] Rezkallah EM, Elsaify A, Tin SM, Elsaify W. Diagnostic accuracy of ultrasonography in axillary staging in breast cancer patients. J Med Ultrasound 2023; 31(4): 293-7. DOI: 10.4103/jmu.jmu_99_22

[13] Sidhwani SK, Khan MW, Suhag AH, Najeeb S, Humayun L, Syed S. Accuracy of ultrasound-guided core biopsy for staging axilla in clinically node-negative patients with invasive breast cancer taking histopathology as gold standard. J Dow Univ Health Sci (JDUHS) 2024; 18(3): 137-43.

[14] Mwaniki D. Diagnostic accuracy of axillary ultrasound in predicting nodal metastasis among patients with early breast cancer at Aga Khan University Hospital, Nairobi. Dissertation. East Africa: Aga Khan University 2022.

[15] Lim GH, Allen JC, Lee YS, Teo SY, Lau LC, Win T, *et al.* Use of axillary ultrasound to guide breast cancer management in the genomic assay era. Breast Dis 2024; 43(1): 19-23. https://doi.org/10.3233/BD-230032

[16] Loonis AS, Chesebro AL, Bay CP, Portnow LH, Weiss A, Chikarmane SA, *et al.* Positive predictive value of axillary lymph node cortical thickness and nodal, clinical, and tumor characteristics in newly diagnosed breast cancer patients. Breast Cancer Res Treat 2024; 203(3): 511-21. https://doi.org/10.1007/s10549-023-07155-z

[17] Georgieva M, Rennert J, Brochhausen C, Stroszczynski C, Jung EM. Suspicious breast lesions incidentally detected on chest computer tomography with histopathological correlation. Breast J 2021; 27(9): 715-22. https://doi.org/10.1111/tbj.14259

[18] Cohen PR. Pleomorphic appearance of breast cancer cutaneous metastases. Cureus 2021; 13(12): e20301. DOI: 10.7759/cureus.20301

[19] Łuczyńska E, Pawlak M, Popiela T, Rudnicki W. The role of ABUS in the diagnosis of breast cancer. J Ultrason 2022 ; 22(89): 76. DOI: 10.15557/JoU.2022.0014

[20] Abdul Halim AA, Andrew AM, Mohd Yasin MN, Abd Rahman MA, Jusoh M, Veeraperumal V, *et al.* Existing and emerging breast cancer detection technologies and its challenges: A review. Appl Sci 2021; 11(22): 10753. https://doi.org/10.3390/app112210753

[21] Abidi SS, Vohra LM, Kerawala AA, Masroor I, Tahseen MU. Diagnostic accuracy of axillary nodal ultrasound after neoadjuvant chemotherapy in node-positive breast cancer patients: A validation study. J Pak Med Assoc 2022; 72(1): S25-S9. doi: 10.47391/JPMA.AKU-06

[22] Zhang YN, Wang CJ, Xu Y, Zhu QL, Zhou YD, Zhang J, *et al.* Sensitivity, specificity and accuracy of ultrasound in diagnosis of breast cancer metastasis to the axillary lymph nodes in chinese patients. Ultrasound Med Biol 2015; 41(7): 1835-41. doi: 10.1016/j.ultrasmedbio.2015.03.024

[23] Hall SJ, Brown SE, Porter GJR, Steel J, Paisley K, Watkins R, *et al.* Axillary ultrasound in staging breast cancer: Diagnostic accuracy and effect on subsequent axillary surgery - the Plymouth experience. Breast Cancer Res 2009; 11(Suppl 2): P21. https://doi.org/10.1186/bcr2391

[24] Olfatbakhsh A, Haghighat S, Sari F, Beheshtian T, Hashemi EA, Jafari M. The accuracy of preoperative axillary ultrasound in the diagnosis of lymph node involvement at Motamed cancer institute, Iran. Int J Cancer Manag 2020; 13(4): e96383. doi: 10.5812/ijcm.96383.

[25] Sood R, Rositch AF, Shakoor D, Ambinder E, Pool KL, Pollack E, *et al.* Ultrasound for breast cancer detection globally: A systematic review and meta-analysis. J Global Oncol 2019; 5: 1-17. https://doi.org/10.1200/JGO.19.00127

[26] Dan Q, Zheng T, Liu L, Sun D, Chen Y. Ultrasound for breast cancer screening in resource-limited settings: Current practice and future directions. Cancers 2023; 15(7): 2112. https://doi.org/10.3390/cancers15072112

[27] Wang J, Ben Z, Gao S, Lyu S, Wei X. The role of ultrasound elastography and virtual touch tissue imaging in the personalized prediction of lymph node metastasis of breast cancer. Gland Surg 2021; 10(4): 1460-9. https://doi.org/10.21037/gs-21-199

Received: September 01, 2025 Revised: November 11, 2025 Accepted: November 13, 2025

© 2025. The Authors, National Journal of Health Sciences.
This is an open access article distributed in accordance with the Creative Commons Attribution Non Commercial (CC BY- NC 4.0) license, which permits others to distribute, remix, adapt, build upon this work non- commercially, and license their derivative works on different terms, provided the original work is properly cited, appropriate credit is given, any changes made indicated, and the use is non-commercial. See: http://creativecommons.org/licenses/by-nc/4.0/.